

Case 2

Physician

Ken Symington, MD

Location

Sacred Heart Hospital, Spokane, Washington

Patient

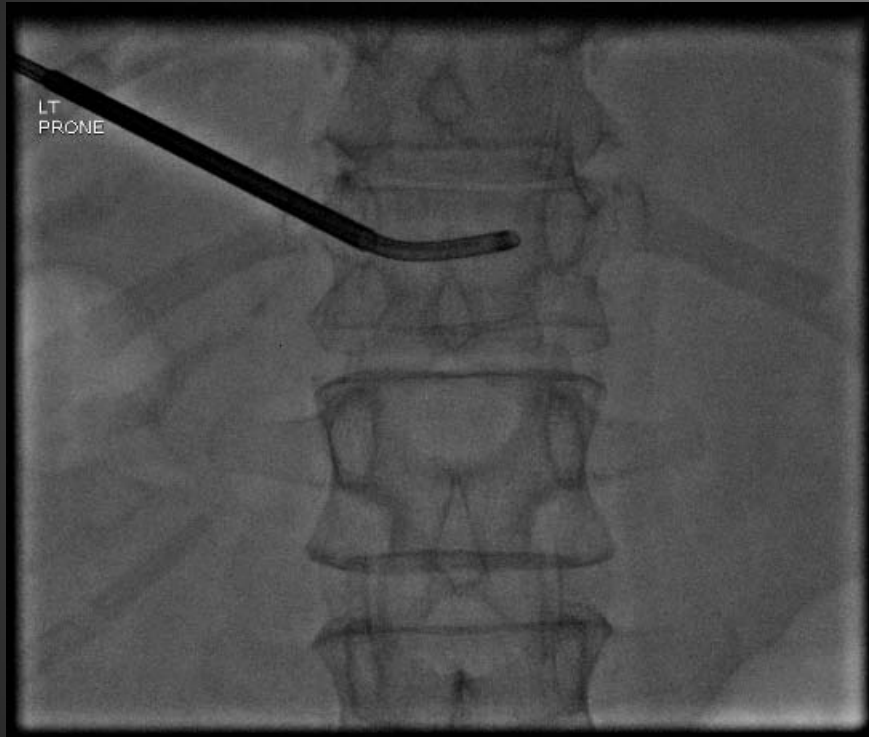Age: 50

Gender: Female

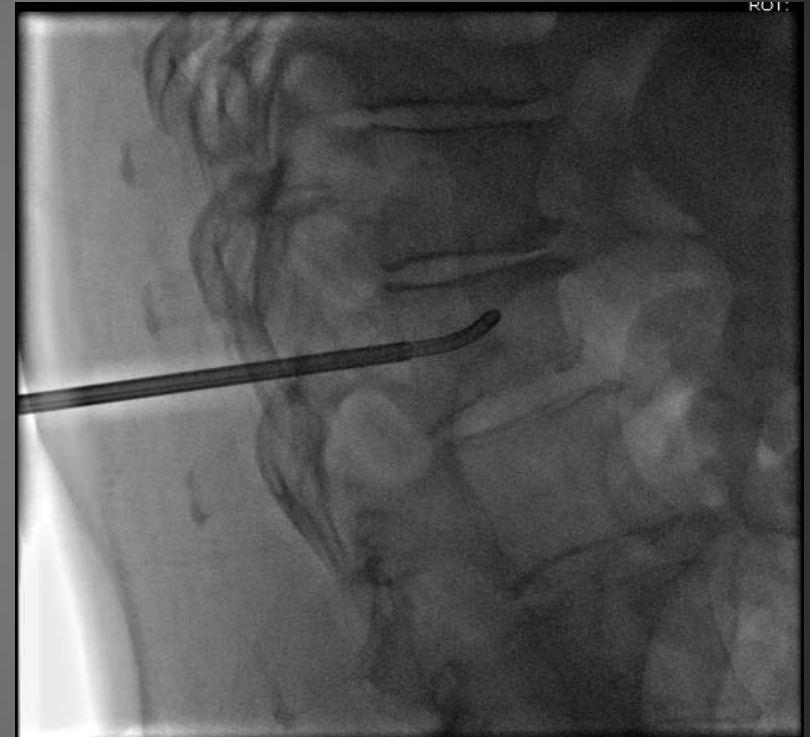
Fracture Type: Traumatic Fracture

Vertebra: T12

50 F
Traumatic Fracture
T12



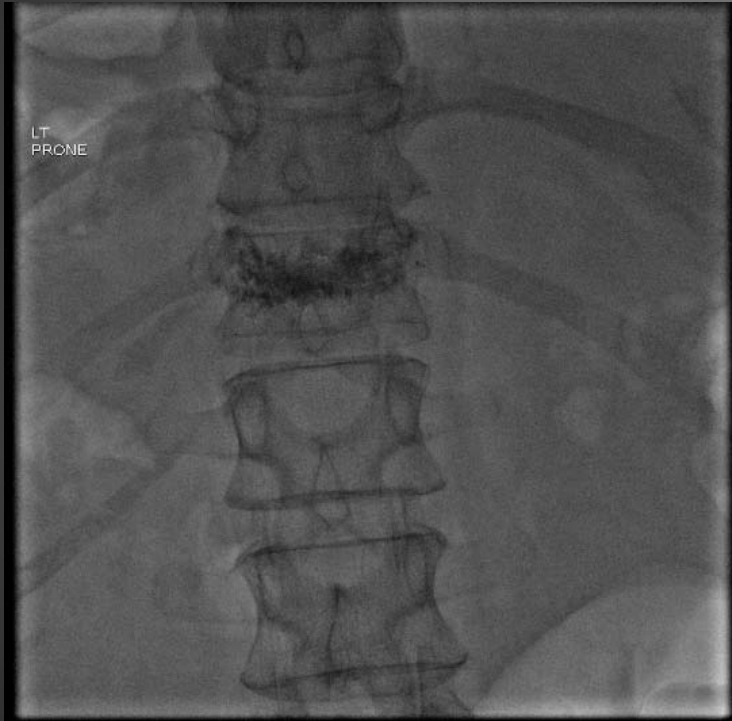
AP



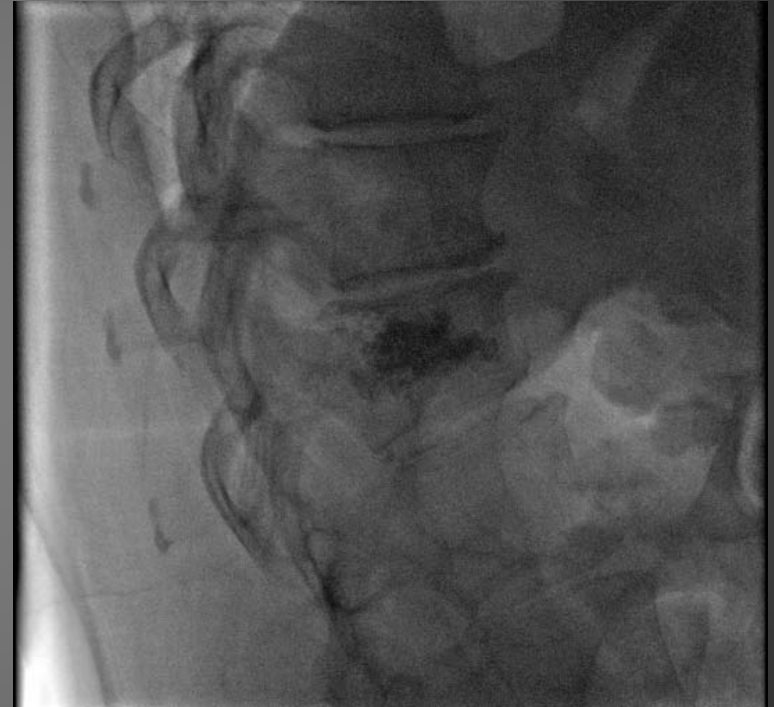LAT

Access to T12 vertebral through unipedicular approach and creation of channel across midline

50 F
Traumatic Fracture
T12



AP



LAT

Final uniform cement fill

Result

- Traumatic fracture with very hard bone in pedicle and vertebral body
- Excellent fill
- No extravasation