

# Case 1

## Physician

Marc Weinstein, MD

## Location

Tampa General Hospital

## Patient

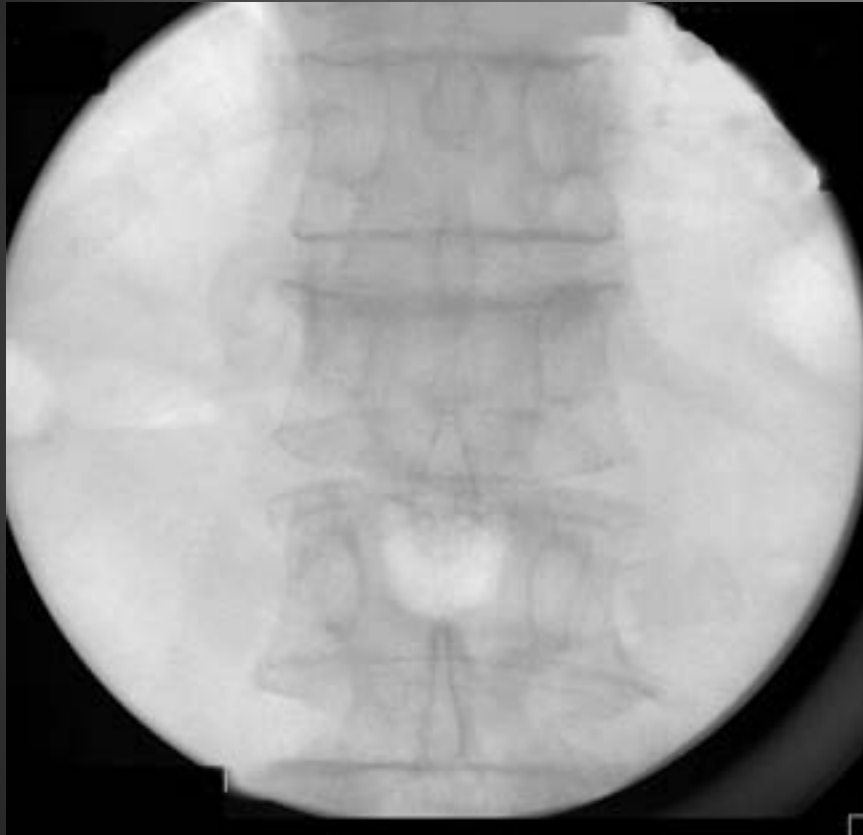Age: 74

Gender: Male

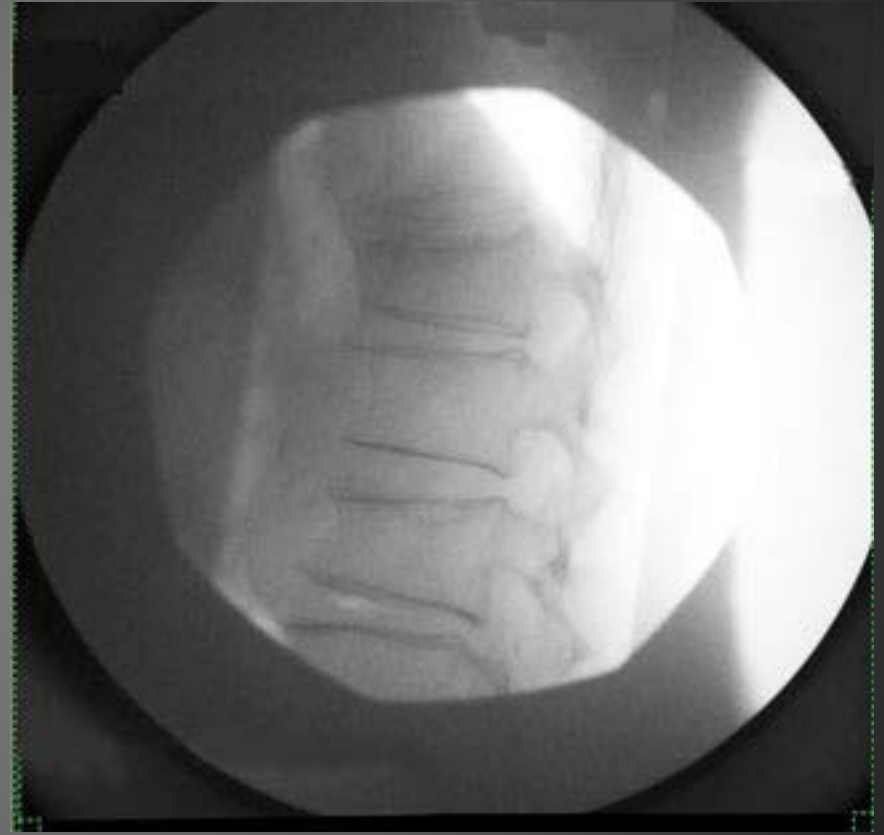Fracture Type: Wedge Fracture

Vertebra: T12

79 M  
Wedge Fracture  
T12

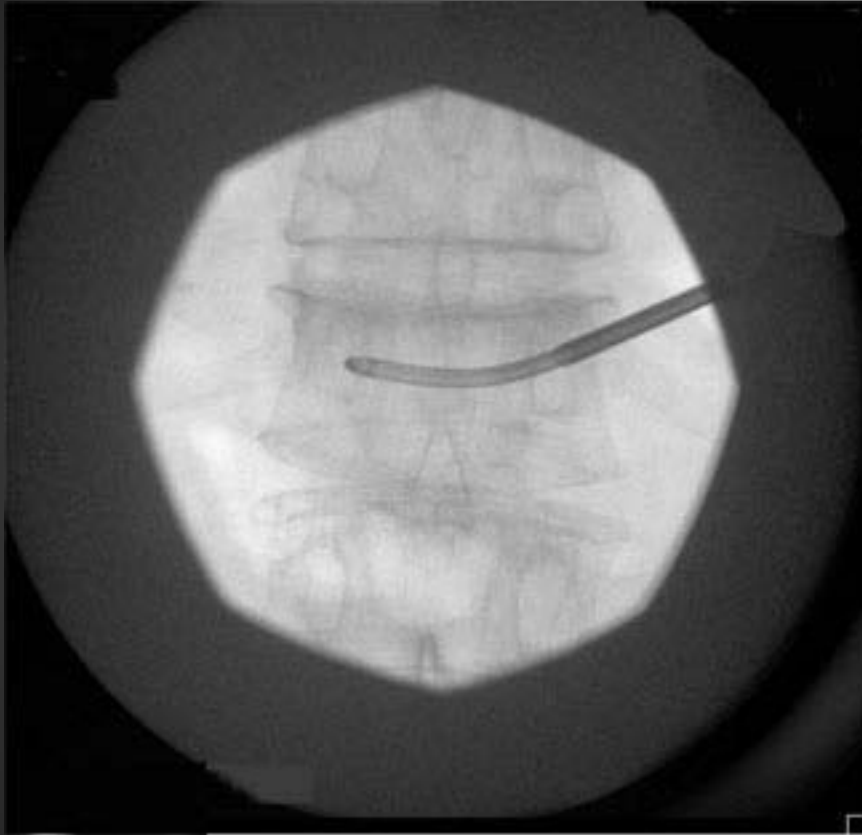


AP

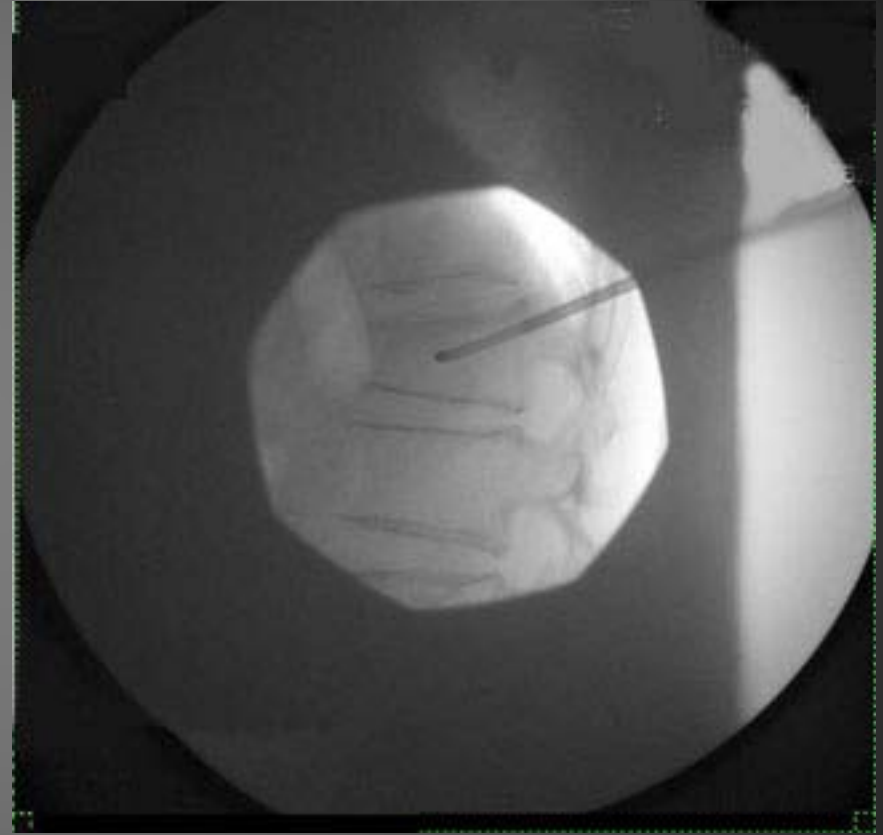


LAT

79 M  
Wedge Fracture  
T12



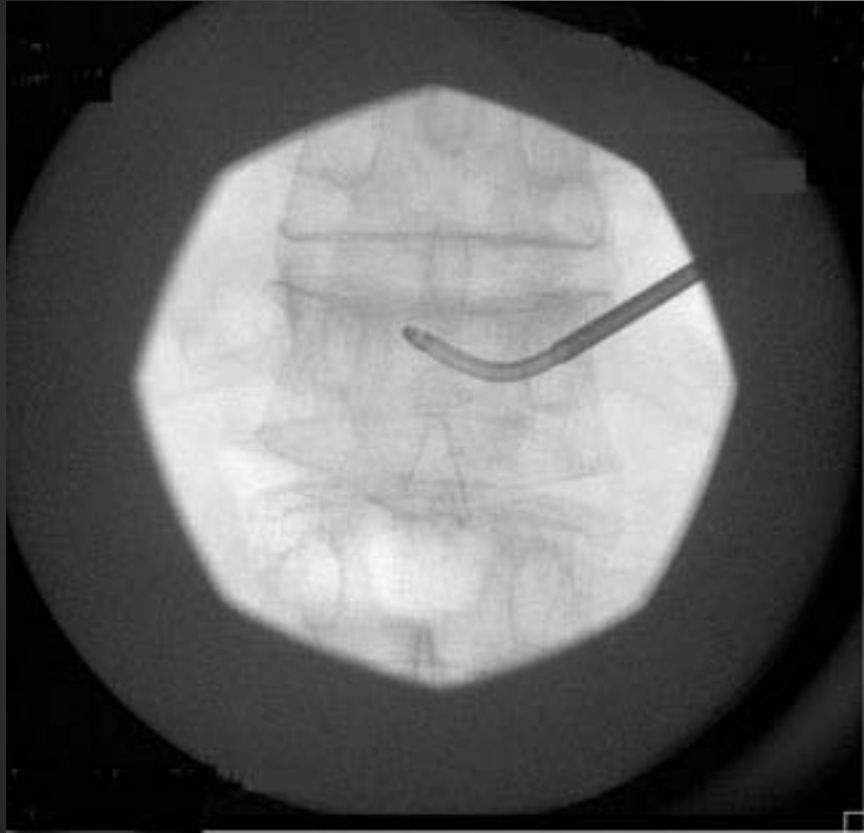
AP



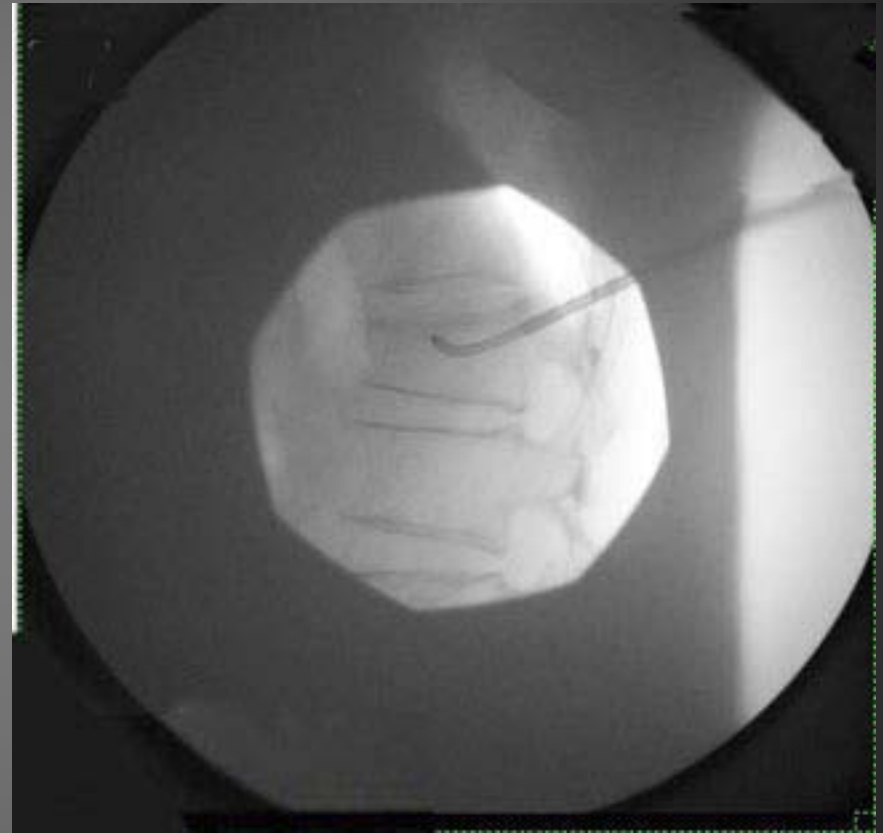
LAT

Introduction of Osseoflex Steerable Needle through unipedicular approach and creation of first channel

79 M  
Wedge Fracture  
T12



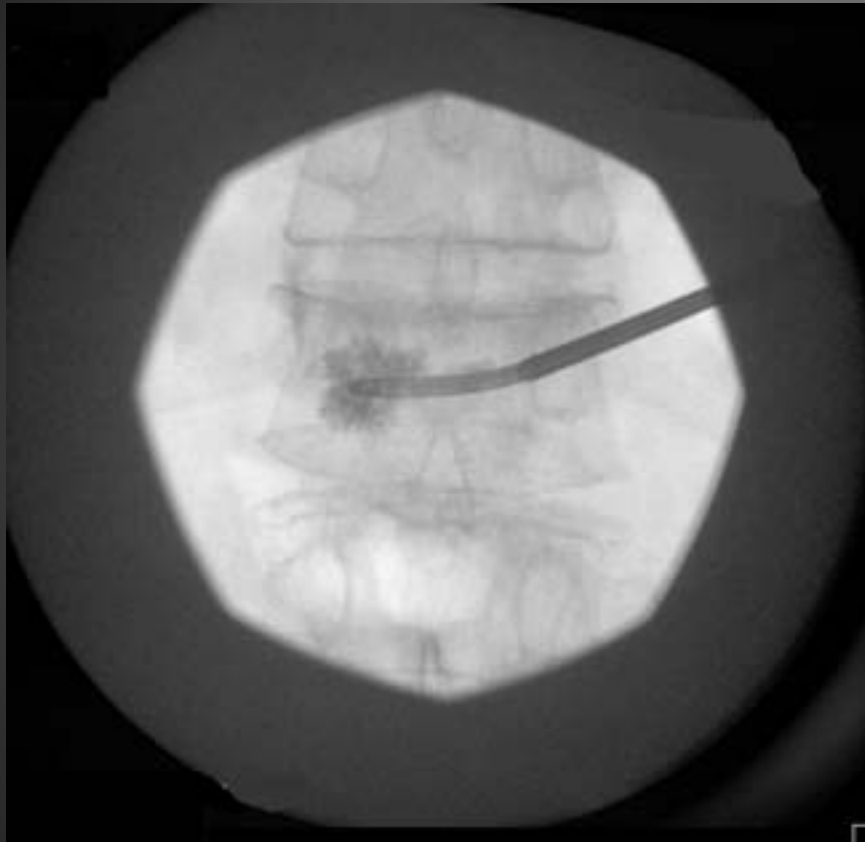
AP



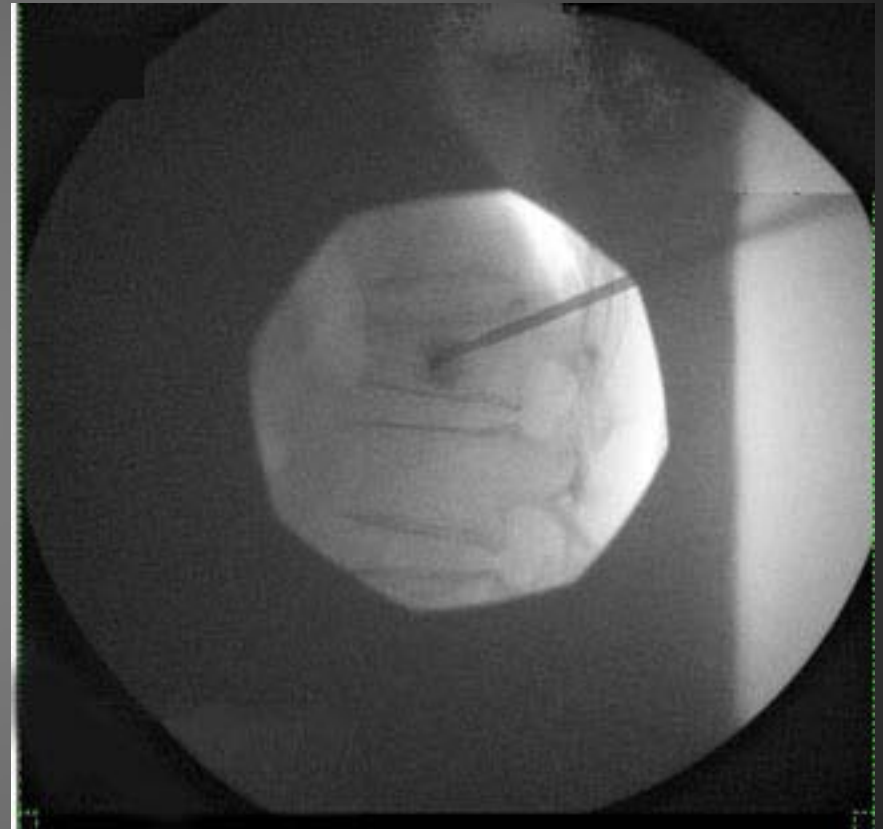LAT

Creation of second channel

79 M  
Wedge Fracture  
T12



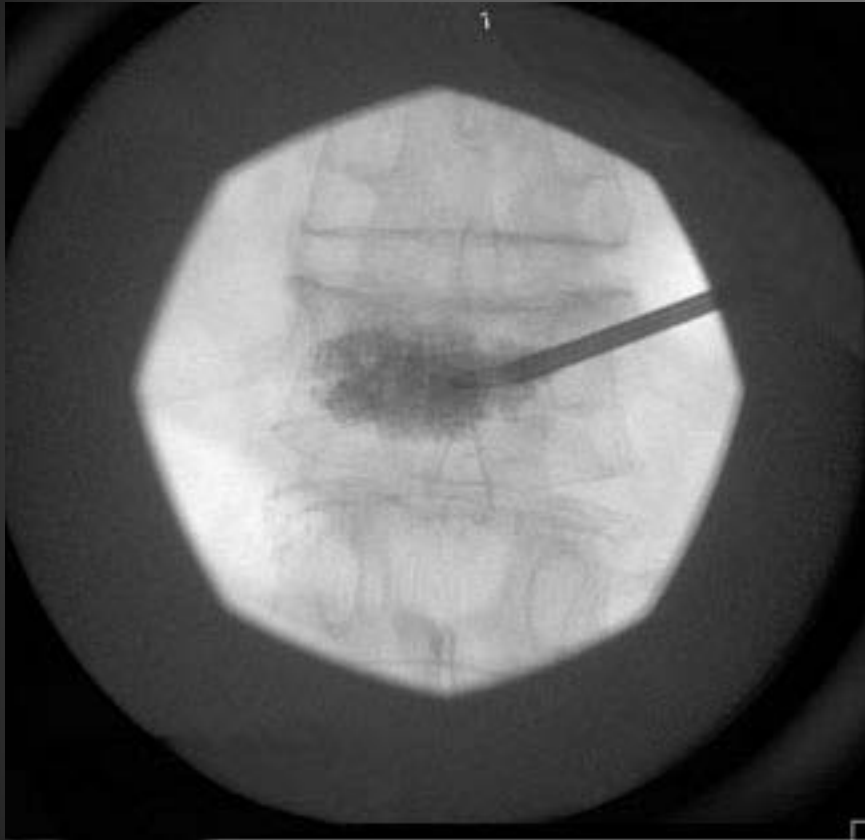
AP



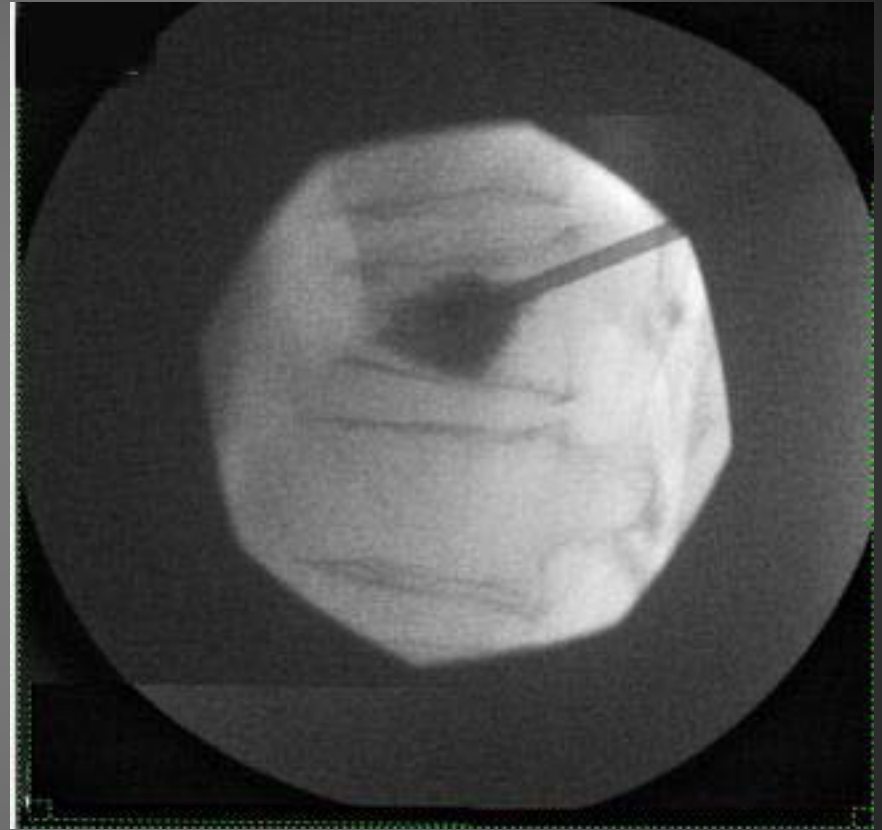
LAT

Delivery of bone cement through Osseoflex Steerable Needle.

79 M  
Wedge Fracture  
T12



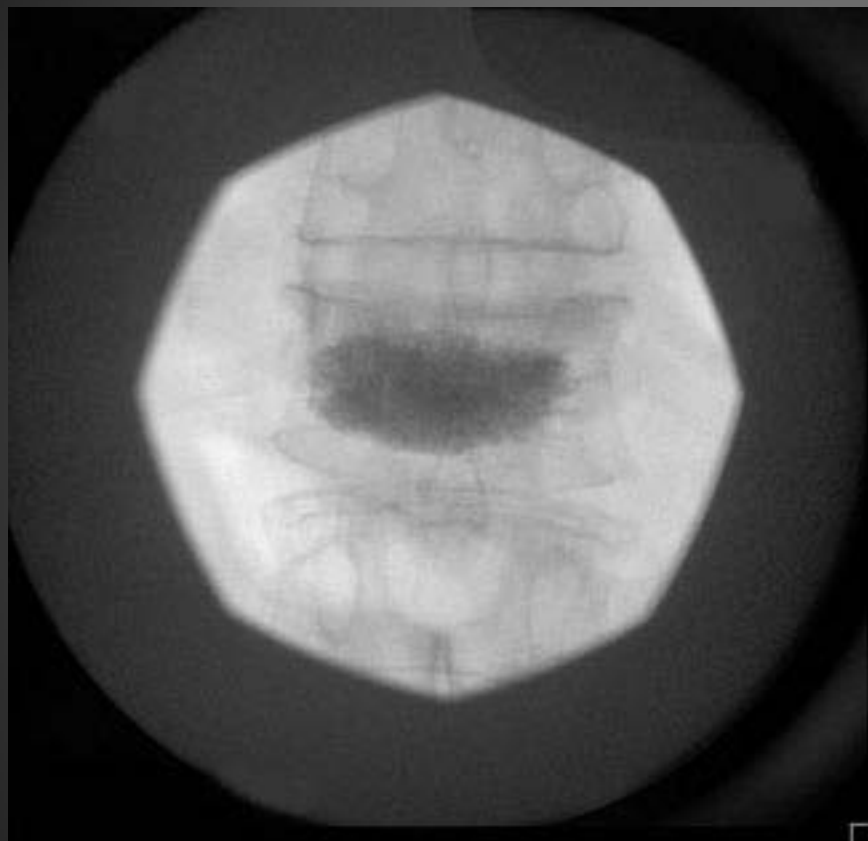
AP



LAT

Delivery of bone cement through Osseoflex Steerable Needle.

79 M  
Wedge Fracture  
T12



AP



LAT

Final result

# Result

- Excellent fill
- Stabilization of fracture
- Reduction in pain
- No extravasation